



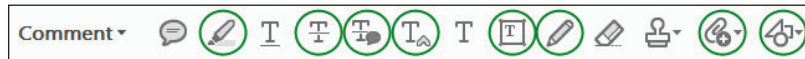## Page Proof Instructions and Queries

**Journal Title:** The International Journal of Lower Extremity Wounds

**Article Number:** 945559

Thank you for choosing to publish with us. This is your final opportunity to ensure your article will be accurate at publication. Please review your proof carefully and respond to the queries using the circled tools in the image below, which are available in Adobe Reader DC\* by clicking **Tools** from the top menu, then clicking **Comment**.

Please use *only* the tools circled in the image, as edits via other tools/methods can be lost during file conversion. For comments, questions, or formatting requests, please use . Please do *not* use comment bubbles/sticky notes .



\*If you do not see these tools, please ensure you have opened this file with **Adobe Reader DC**, available for free at [get.adobe.com/reader](http://get.adobe.com/reader) or by going to Help > Check for Updates within other versions of Reader. For more detailed instructions, please see [us.sagepub.com/ReaderXProofs](http://us.sagepub.com/ReaderXProofs).

No.	Query
	Please note that we cannot add/amend ORCID iDs for any article at the proof stage. Following ORCID's guidelines, the publisher can include only ORCID iDs that the authors have specifically validated for each manuscript prior to official acceptance for publication.
	Please confirm that all author information, including names, affiliations, sequence, and contact details, is correct.
	Please review the entire document for typographical errors, mathematical errors, and any other necessary corrections; check headings, tables, and figures.
	Please confirm you have reviewed this proof to your satisfaction and understand this is your final opportunity for review prior to publication.
	Please confirm that the Funding and Conflict of Interest statements are accurate.
1	Please verify the author names appear as forename followed by the surname.
2	Please insert degree(s) for all authors.

# Macrophage Activation and M2 Polarization in Wound Bed of Diabetic Patients Treated by Dermal/Epidermal Substitute Nevelia

The International Journal of Lower Extremity Wounds  
1–7

© The Author(s) 2020



Article reuse guidelines:

sagepub.com/journals-permissions

DOI: 10.1177/1534734620945559

journals.sagepub.com/home/ijl



Manuela Montanaro<sup>1</sup>, Marco Meloni<sup>1</sup> , Lucia Anemona<sup>1</sup>,  
Laura Giurato<sup>1</sup>, Manuel Scimeca<sup>1</sup>, Valentina Izzo<sup>1</sup>,  
Francesca Servadei<sup>1</sup>, Artem Smirnov<sup>1,2</sup>, Eleonora Candi<sup>1,3</sup>,  
Alessandro Mauriello<sup>1</sup>, and Luigi Uccioli<sup>1</sup>  [AQ: 1][AQ: 2]

## Abstract

Clinical evidences have shown good results using dermal/epidermal substitutes (DESs) to treat diabetic foot ulcers. Recent studies suggest that, in addition to their scaffold action, DESs may favor wound healing by influencing wound bed inflammatory cells. This study aims to investigate whether DES may influence the inflammatory infiltrate and macrophages polarization toward a reparative phenotype. Fifteen diabetic patients with chronic foot ulcers have been randomly enrolled: 5 treated only by standard of care, served as control group (CG), and 10 treated with DES composed of type I bovin collagen (Nevelia, SYMATESE) considered as test group (TG). A biopsy was taken at baseline (T0) and after 30 days (T30). From bioptic paraffin specimen histological, immunohistochemical, and immunofluorescence analysis was performed. Immunohistochemistry reactions evaluated the number of M1 macrophage (CD68<sup>+</sup>) and M2 macrophage (CD163<sup>+</sup>). TG patients displayed general macrophage activation and their greater polarization toward M2 subpopulation 30 days after DES implant, compared with CG. From T0 to T1 there was a significant decrease of CD68<sup>+</sup> ( $674 \pm 40$  and  $455 \pm 38$  mm<sup>2</sup>, respectively;  $P < .001$ ) and significant increase of CD163<sup>+</sup> ( $102 \pm 21$  positive cells/mm<sup>2</sup> and  $366 \pm 42$  positive cells/mm<sup>2</sup>, respectively;  $P < .001$ ). Confocal microscopy confirmed an increase of M2 cells as expressed by the reduced CD68<sup>+</sup>/CD163<sup>+</sup> ratio. After 6 months of observation 6 patients (60%) of the TG completely healed, while only 1 patient (20%) healed in the CG ( $P < .01$ ). The tested DES makes possible to treat diabetic foot ulcers inducing tissue reparative processes through macrophage activation and M2 reparative polarization.

## Keywords

diabetes, diabetic foot ulcers, macrophage polarization, wound healing, dermal epidermal substitutes, DES

## Background

Diabetic foot ulcers (DFUs) are one of the most severe complications of diabetic patients, and they occur in the natural evolution of the disease as a long-term complication.<sup>1-4</sup> It is caused by diabetes combined with different degrees of lower extremity vascular disease and neuropathy, and the wound may not heal for long time, leading to amputation.<sup>5-7</sup> DFUs are characterized by a chronic inflammation, which consists of a low and persistent macrophagic and lymphocytic inflammatory infiltrate, without any progression toward recovery and healing.<sup>8</sup>

Recent studies demonstrated new valid therapeutic alternatives offered by regenerative medicine, mainly in the treatment of chronic and very large ulcerations. Among these,

the use of dermal and epidermal substitutes (DESs) may improve wound management and recovery.<sup>9-12</sup>

In our previous study we have demonstrated the ability of a bilayer DES, constituted by a layer of collagen plus a layer of silicon, to promote healing of diabetic foot lesions.<sup>12</sup> It has been hypothesized that its regenerative ability might

<sup>1</sup>University of Rome "Tor Vergata," Rome, Italy

<sup>2</sup>Ludwig Institute for Cancer Research, University of Oxford, Oxford, UK

<sup>3</sup>IDI-IRCCS, Rome, Italy

### Corresponding Author:

Luigi Uccioli, Department of Systems Medicine, University of Rome Tor Vergata, Via Montpellier 1, Roma 00133, Italy.

Email: luigi.uccioli@ptvonline.it

be related to its composition and structure made by 2 layers: collagen and silicon. The natural component is a 3-dimensional porous matrix of type 1, purified, stabilized, bovine-origin collagen, the main protein component of the human body and major component of the extracellular matrix. It acts as a scaffold to allow cell migration, adhesion, multiplication, differentiation, and the complete integration of the dermal sheet with the wound bed, to support the neo tissue 3-dimensional formation, with customized properties to shape tissue reconstruction.<sup>13</sup> Silicon layer is a synthetic structure composed of polyester-reinforced silicon sheeting. It can act as an epidermal layer capable of protecting the wound from infection and it may guarantee the best environment for healing. Due to these specific characteristics, the simplest hypothesis is that the tissue repair occurs because the DES 3-dimensional scaffold gives the structural support to the wound cells even if a collagen effect on modulating other reparative factors cannot be excluded, since *in vitro* evidences support the hypothesis that collagen contained in DESs is able to influence the macrophage phenotype in the ulcer bed.<sup>14-16</sup>

Therefore, the aim of this study is to evaluate whether if this specific DES composed of type 1 bovine collagen is able to activate the plasticity of wound macrophages, by inducing their polarization from M1 inflammatory to M2 reparative phenotype.

## Materials and Methods

This case-control study included 15 consecutive patients with chronic DFUs with a size  $>5$  cm<sup>2</sup>, nonischemic, noninfected, belonging to stage A and grade 1 or 2 according to the Texas wound classification.<sup>17</sup>

Patients were randomly assigned into 2 groups: 10 patients in test group (TG) were treated by a specific DES composed of type 1 bovine-origin collagen in addition to standard of care (SOC), while 5 patients considered as control group (CG) were treated exclusively by SOC including a saline gauze. Offloading was provided to all patients. An ankle-high removable walker was prescribed to all patients included.

Chronic DFUs were defined in the case of size ulcer reduction less than 50% after 4 weeks of SOC.<sup>18</sup>

Absence of infection was defined according to the Infectious Diseases Society of America classification.<sup>19</sup> Absence of significant ischemia was defined by TcPO<sub>2</sub> (transcutaneous partial oxygen pressure) values  $>25$  mm Hg.<sup>20</sup>

Exclusion criteria were presence of infection, ischemia, ulcer size  $<5$  cm<sup>2</sup>, wound area reduction  $>50\%$  in the last 4 weeks, and treatment plan interfering with the immunologic response (systemic steroid therapy, presence of concomitant chronic inflammatory diseases, cancer, etc).

The study protocol was approved by the Independent Ethical Committee. All experimental procedures were carried

out according to the Code of Ethics of the World Medical Association (Declaration of Helsinki). Informed consent was obtained from all patients prior to surgery. The specimens were handled and carried out in accordance with approved guidelines. Each patient provided informed written consent for every surgical procedure.

## Dermal-Epidermal Substitute

The bilayer DES used is a 3-dimensional porous matrix, purified, stabilized, bovine-origin type-1 collagen (Nevelia, SYMATESE, Chaponost, France). The collagen matrix is supported by a strong silicon sheet enabling firm coverage of the wound bed. After surgical debridement the DES was firmly placed over the lesion through suture. The silicon sheet was covered by sterile gauzes and bandage. After the DES application all patients were followed monthly, as outpatients, for 6 months or until healing was achieved. During the follow-up, sharp debridement was performed in the CG while only clinical observation was performed in the TG until the silicon sheet was not removed.

In all patients, bioptic samples were collected by the wound edge at basal (time 0) and 30 days after (time 30). Biopsy was performed through punch biopsy. It was performed in the edge because it was the wound site more easily accessible in patients treated with DES. For the TG, "time 0" was considered at the timing of DES application and "time 30" at 30 days after DES application. For the CG 2 samples were collected, respectively, at inclusion time and 30 days after.

According to our previous study we removed the DES silicon sheet only after 8 to 12 weeks,<sup>12</sup> therefore we were not able to evaluate and compare ulcer size between TG and CG at "time 30."

After fixation in 10% buffered formalin for 24 hours, tissues were paraffin embedded. For each sample 3- $\mu$ m-thick serial sections were obtained in order to perform histological and immunohistochemical analyses.

## Immunohistochemistry and Immunofluorescence

In detail, immunohistochemistry reactions were used to study the monocyte-macrophage cells (Table 1). In order to evaluate the different state of macrophage activation and polarization in treated and untreated groups, a semiquantitative evaluation of CD68 (KP1 mouse monoclonal antibody, general macrophage marker, 1: 200; Abcam), CD38 (Rabbit monoclonal, typically M1 macrophage marker, 1:100; Abcam), and CD163 (Rabbit monoclonal, typically M2 macrophage marker, 1:500; Abcam) expressions were performed.

To carry out immunohistochemistry reactions, antigen retrieval was performed on 3- $\mu$ m thick paraffin sections by using Tris-EDTA (ethylenediaminetetraacetic acid) citrate

**Table 1.** Baseline Data of Patients.

	All cases (N = 15)	TG (N = 10)	CG (N = 5)	P (TG vs CG)
Age (years)	70 ± 9.9	69.8 ± 9.4	70.6 ± 9.9	ns
Sex (% male)	60%	60%	60%	ns
Type 2 diabetes (%)	100%	100%	100%	
Diabetes duration (years)	20.4 ± 12.9	20.7 ± 1.3	20.3 ± 0.5	ns
A1c, % (mmol/mol)	7.9 ± 0.2% (63 ± 2)	7.3 ± 2% (56 ± 15)	7.9 ± 5.5% (63 ± 44)	ns
Ischemic heart disease (%)	46%	50%	40%	ns
Carotid artery disease (%)	20%	20%	20%	ns
Systolic blood pressure (mm Hg)	135 ± 15	133 ± 17	135 ± 15	ns
Diastolic blood pressure (mm Hg)	80 ± 2	77 ± 9	80 ± 9	ns
Total cholesterol (mg/dL)	156 ± 29	157 ± 23	153 ± 45	ns
HDL cholesterol (mg/dL)	46 ± 13	48 ± 16	43 ± 11	ns
Triglycerides (mg/dL)	148 ± 88	151 ± 38	145 ± 33	ns
LDL (mg/dL)	96 ± 32	99 ± 4	92 ± 2	ns
TcPO <sub>2</sub> (mm Hg)	39.6 ± 3.5	40.9 ± 3.38	39.6 ± 4.16	ns
Ulcer size (cm <sup>2</sup> )	21.8 ± 4.1	21.7 ± 4.3	22.2 ± 4.2	ns
Ulcer duration (days)	87.4 ± 17.4	88.7 ± 18.3	84.8 ± 17.3	ns
TUC grade 1 [N (%)]	3/15 (20%)	2/10 (20%)	1/5 (20%)	ns
TUC grade 2 [N (%)]	12/15 (80%)	8/10 (80%)	4/5 (20%)	ns

Abbreviations: TG, test group; CG, control group; ns, not significant; HDL, high-density lipoprotein; LDL, low-density lipoprotein; TUC, Texas University Classification.

buffer, pH 7.8, for 30 minutes at 95 °C. Sections were then incubated for 1 hour at room temperature with primary antibodies (listed in Table 1). Washings were performed with PBS (phosphate-buffered saline)/Tween20, pH 7.6. Reactions were revealed by HRP-DAB Novolink Detection Kit (Leica Biosystem). All markers were evaluated with the support of a digital software (ImageViewer, Ventana, Roche) by 2 blind observers by counting the number of positive cells; results were reported as number of positive cells/mm<sup>2</sup>.

To confirm immunohistochemical results and analyze co-localization of CD68 and CD163 markers, a confocal microscopy analysis has been carried out. Briefly, 3- to 4- $\mu$ m-thick paraffin sections were dewaxed and dehydrated, then antigen retrieval was performed using Tris-EDTA citrate pH 7.8 buffer for 10 minutes in a microwave stove. Auto-fluorescence was reduced by tetrahydroborate solution for 40 minutes. Sections were then incubated overnight at 4 °C with CD68 antibody (1:200) diluted in 5% goat serum. Washings were performed with PBS/Tween (0.1%) and the sections were incubated for 1 hour at room temperature with the CD163 antibody (1:1000) diluted in 5% goat serum. After the washes, the slides were incubated for 1 hour with the appropriate secondary antibodies conjugated with Alexa Fluor 488 or 568 (Thermo Fisher) and DAPI (1  $\mu$ g/mL).

The slides were then mounted using ProLong Antifade (Thermo Fisher). Images were acquired with a Nikon A1 confocal laser microscope (Nikon).

## Outcomes

The major end point considered was the macrophage characterization at “time 30.” The only clinical end point considered was healing after 6 months of follow-up. Healing was considered in case of complete epithelization target wound. Data of TG and CG were reported and compared.

## Statistical Analysis

Data were analyzed using SPSS version 16.0 (SPSS Inc) software. The sample size was calculated by power analysis by adopting the 2-tailed test of the null hypothesis with  $\alpha = 0.05$  and a value of  $\beta = 0.10$  as the second type error and, therefore, a test power equal to 90%.

Continuous variables were expressed as the mean  $\pm$  standard error of mean. The Shapiro-Wilk test was used to statistically assess the normal distribution of the data. Comparisons between continuous variables were performed using the independent Student *t* test or the Wilcoxon rank sum test. Categorical data were analyzed using  $\chi^2$  test or Fisher’s exact test.

## Results

### Clinical Findings

Baseline data of whole population and test/control groups are summarized in Table 1. There were no differences between TG and CG for age, sex, duration and type of diabetes,

diabetic long-term complications, comorbidities, as well as cardiovascular risk factors. Furthermore, there were no significant differences in terms of ulcer's characteristics, including size and duration. All wounds were localized in the plantar surface for both groups.

### Clinical DFU Outcomes

After 6 months of observation, 6 patients (60%) of the TG completely healed, while only 1 patient (20%) healed in the CG ( $P < .01$ ). No amputations or deaths were recorded.

### Histological Findings

Analysis of all biopsies collected at "time 0" showed the presence of skin ulcerations associated with fibrin-necrotic material and several neutrophils (Figure 1A and B). In addition, we observed a small inflammatory area consisting of granulocytes and a loose connective tissue characterized by the presence of thin-walled neo-formed vessels close to the lesion; moreover, many inflammatory cells, like lymphocytes, plasma cells, monocytes-macrophages, and rare neutrophil granulocytes, were present in these neo-vascularized areas. Furthermore, these numerous small vessels presented hyaline wall, compatible with diabetic hyaline arteriosclerosis scenario.

In TG, at "time 30," an extensive dense connective tissue, consisting of thick collagen-repair tissue associated with neo-formed thin-walled vessels and numerous elongated cells (probably fibroblasts), was found, associated in the subcutaneous tissue to a decrease of vessels with diabetic hyaline arteriosclerosis wall (Figure 1C). Nevertheless, at "time 30," biopsies of CG showed a morphologic and histologic scenario similar to the one observed at "time 0."

As described in Table 2, the immunohistochemical evaluation of monocyte-macrophagic population allowed to demonstrate, at "time 0," the presence of macrophage infiltrate, consisting largely of CD38<sup>+</sup> (M1) and a smaller quantity of CD163<sup>+</sup> (M2) macrophages. In TG the density of macrophage cells was found to be  $230 \pm 42$  cells/area CD38<sup>+</sup> and  $102 \pm 21$  cells/area CD163<sup>+</sup> (Figure 1G and H), while in CG  $262 \pm 32$  cells/area CD38<sup>+</sup> and  $82 \pm 24$  cells/area CD163<sup>+</sup> were estimated (Figure 1D and E). No significant differences were observed between the 2 groups (Figure 1D, E, G, and H).

In TG, at "time 30," a significant increase in M2 macrophages CD163<sup>+</sup> was observed ( $366 \pm 42$  cells/area;  $P < .01$ ; Figure 1I), compared with CG which resulted to be unchanged with  $60 \pm 22$  cells/area CD163<sup>+</sup> (Figure 1F).

### Confocal Microscopy

Confocal microscopy (Figure 1L-Q) was utilized to study the percentage of CD163<sup>+</sup> macrophages, evaluating the co-localization of CD68 and CD163 markers. Double

immunofluorescence confirms the significant increase of CD163<sup>+</sup> cells in TG after 30 days. In TG group, "time 0" bioptic samples showed that CD163<sup>+</sup> was 27.3% of the whole CD68<sup>+</sup> macrophage population. At "time 30" CD163<sup>+</sup> macrophages significantly increased, becoming 63.9% of the whole macrophage population ( $P < .01$  vs baseline).

### Discussion

A normal wound healing proceeds in a timely sequence of repair, whose phases overlap one another, and the whole process is able to restore anatomic and functional results.<sup>20</sup> In contrast to this, in pathological conditions, the timely sequence of repair is lost and the ulcers do not heal as a result of chronic inflammatory conditions. For this reason, reparative processes in chronic nonhealing wounds, including DFUs, are delayed and become arrested in the inflammatory phase.<sup>21</sup>

Recently DESs have been used to speed wound healing in neuropathic ulcers or large postsurgical wounds.<sup>9-12</sup>

In our previous experience, a type 1 purified bovine collagen DES has been used to promote healing of postischemic noninfected foot ulcers with convincing clinical evidences about its ability to support dermal/epidermal repair processes.<sup>12</sup> However, the following issues have arisen: does the collagen act as a passive tridimensional template or it also has other biological activities able to stimulate reepithelization? May have a role in the activation and polarization of M2 macrophages? These questions are directly related to improve the knowledge of biomaterial-macrophage interaction, since a positive interaction could help in overcoming the long-standing inflammatory phase present in chronic wounds.<sup>16</sup>

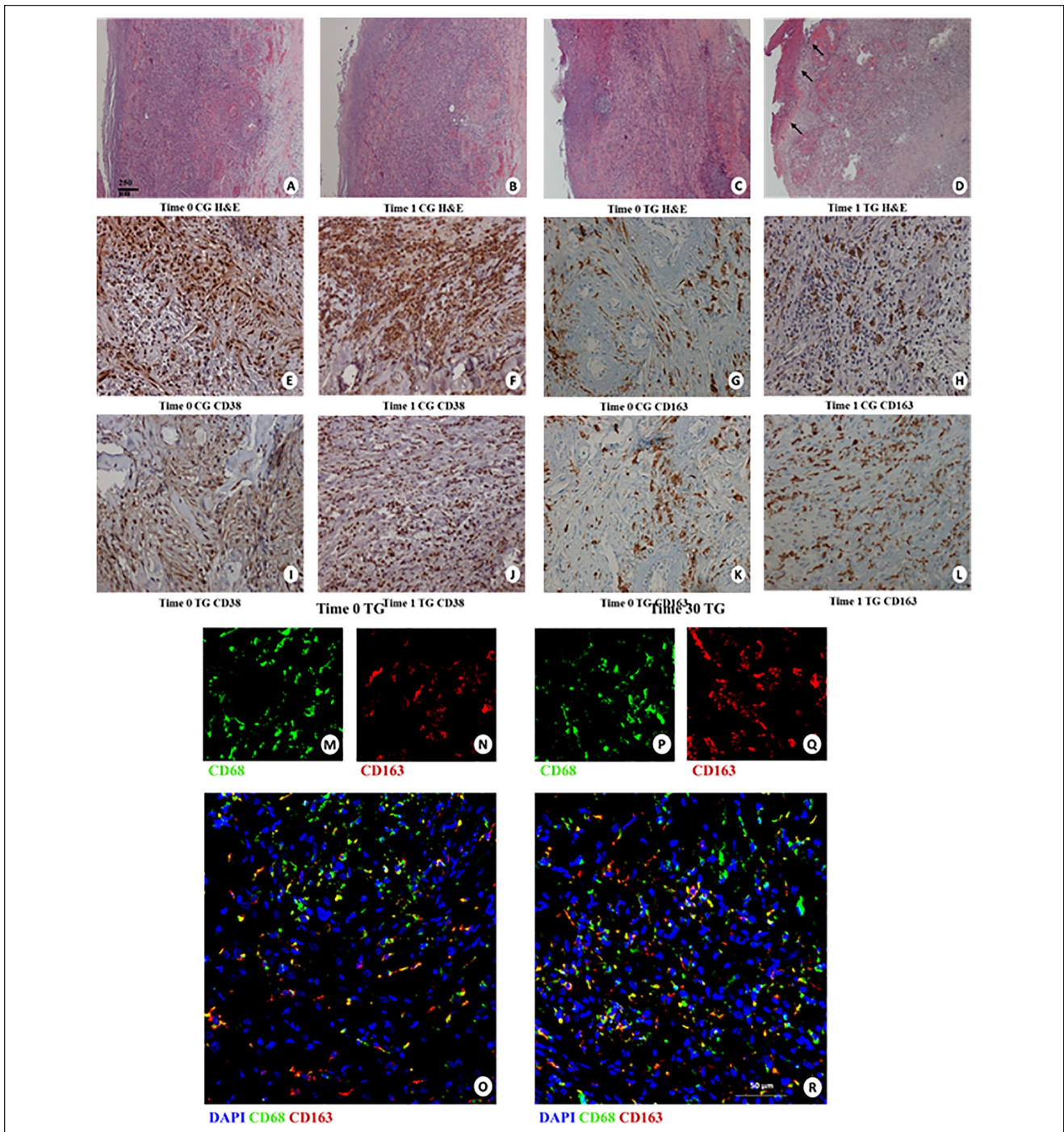
This study, even in a small group of patients, confirms the ability of this type 1 bovine collagen DES in stimulating healing processes also in nonhealing ulcers and gives additional knowledge on its mechanism of action in stimulating wound healing.

This study has shown that the tested DES, used to treat chronic nonhealing ulcers in diabetic patients, is able to induce a significant increase in M2 macrophages.

TG shows reparative processes related to macrophage activation (increase in density) and polarization (increase in M2 macrophages). This phenomenon is also associated with a reduction of vessels with diabetic hyaline arteriosclerosis.

This effect was not evident in the histological pattern of CG. It could be related to the persistent inflammatory phase and poor effectiveness of dressing used in this specific group.

The study reported a very low rate of healing (1/5) in the CG. Even though the SOC was applied and the foot perfusion was adequate, the authors stated that slow healing rate/process could be related to the large ulcers size and persistent inflammatory process as suggested by histological patterns.



**Figure 1.** (A-I) Morphological aspects and immunohistochemical analysis. In biopsies taken at “Time 0” of control group (CG; A, 4×) and test group (TG; C, 4×), hematoxylin and eosin (H&E) stain shows a large ulceration. After 30 days from the beginning of treatment (“Time 30”), in TG, the H&E image displays an important area of repaired tissue, with a small necrotic superficial region (D, 4×), compared with CG (B, 4×). At “Time 0,” in CG group CD38 immunostaining highlights a large M1 macrophage inflammatory infiltration (E, 20×) with few M2 macrophages positive for CD163 antibody (G, 20×). In this group the amount of CD38<sup>+</sup> M1 and CD163<sup>+</sup> M2 macrophages remains similar after 30 days (respectively, F and H, 20×). In TG group, at “Time 0,” the inflammatory infiltrate is similar to the one observed in CG group (I, CD38 Ab, 20×, and K, CD163 Ab, 20×). On the contrary, after 30 days of treatment, the quantity of CD163<sup>+</sup> M2 macrophages in regenerative tissue significantly increases (L, 20×), while the amount of CD38<sup>+</sup> M1 is reduced. (M-R) Double immunofluorescence staining, using anti-CD68 (green) and anti-CD163<sup>+</sup> CD163<sup>+</sup> double-positive cells at (red) antibodies, shows the increase of the number of CD68 “Time 30” in TG group, as compared with “Time 0.”

**Table 2.** Density of Different Macrophage Cells Evaluate by Immunohistochemistry.

	T0	T1	P (TG vs CG)
<b>TG</b>			
CD38	230 ± 42	135 ± 48	.04
CD163	102 ± 21	366 ± 42	.01
<b>CG</b>			
CD38	262 ± 32	241 ± 36	.73
CD163	82 ± 24	60 ± 22	.69

Abbreviations: TG, test group; CG, control group.

Our study confirms that pro-inflammatory M1 macrophages characterize DFUs in chronic stages,<sup>22</sup> and as a matter of fact that CG did not show any spontaneous evolution toward healing.

In vitro studies report that in the early inflammatory stages of an acute wound, macrophages phagocytize spent neutrophils, while in the later stages, having performed this role, macrophages switch phenotype and are predominantly reparative M2. In chronic wounds M1 to M2 switch is dysregulated, and unlike in acute wounds, macrophages are unable to phagocytize neutrophils.<sup>22-25</sup>

In this study we have shown that the tested DES is able to induce an important macrophage activation, with a very strong switch toward the M2 phenotype. The use of immunofluorescence and confocal microscopy allowed us to observe the co-localization of the 2 macrophage markers (CD68 for both phenotypes and CD163 for the M2 phenotype),<sup>26,27</sup> confirming that macrophage population observed at “time 30” was constituted mainly by M2 phenotype.<sup>28,29</sup>

This study shows how this specific kind of DES induces a general macrophage activation useful for the reparative processes and that the strong anti-inflammatory action in tissue regeneration may be due to the switch from M1 phenotype to M2 phenotype, necessary to stimulate healing.

Therefore, we hypothesize that the use of the tested DES to treat chronic DFUs could stimulate wound healing, inducing selective modulation of macrophage population.

### Limitations

This study, although performed in a tertiary-level diabetic foot clinic, is a single-center study. The study group is composed of a very small number of patients and future researches with larger numbers are useful to confirm or reinforce the potential effect of the DES tested by the authors.

There is no comparison with other dermal substitutes to evaluate if macrophage activation and polarization could be related to the specific use of this type 1 bovine collagen DES or it could be stimulated by other DESs. However Witherel et al,<sup>14</sup> in vitro, have shown differences in the responses of monocyte-derived macrophage, isolated from donor blood, to 4 currently applied wound dressing

biomaterials. A recent article by Zomer et al demonstrates that mesenchymal stromal cells from dermal and adipose tissues induce macrophage polarization to a pro-repair phenotype and improve skin wound healing. However, they show that their CG treated exclusively by DES (integra) has a greater percentage of iNOS (an M1 phenotype marker) and reduced rate of MMR (an M2 phenotype marker) in comparison with cell-treated groups both at day 3 and at day 21.<sup>30</sup> In addition, some clinical differences were described between different DESs.<sup>31</sup> Therefore, a specific effect of the tested DES in inducing M2 polarization is likely.

### Conclusions

According to our results, it is possible to summarize that the tested DES is able to stimulate healing in nonhealing chronic wounds and induce polarization toward repairing M2 macrophages. Therefore, it may represent an effective therapeutic strategy to activate tissue regeneration in pathological healing conditions. Perspective future studies might involve other DESs to verify if the effect is specifically related to this specific DES we have used in our study or if it is a class effect that is present in other DESs.

### Author Contributions

Principal investigator, Methodology, Original draft preparation, Revision and approval: Manuela Montanaro; Revision and approval: Marco Meloni; Investigation, Validation, Revision and approval: Lucia Anemona; Revision and approval: Laura Giurato; Methodology, Review and editing, Revision and approval: Manuel Scimeca; Revision and approval: Valentina Izzo; Review and editing, Revision and approval: Francesca Servadei; Methodology, Revision and approval: Artem Smirnov; Review & editing, Revision and approval: Eleonora Candi; Formal analysis, Data Curation, Validation, Review and editing, Revision and approval: Alessandro Mauriello; Investigation, Data curation, Original draft preparation, Revision and approval, Supervision: Luigi Uccioli.

### Declaration of Conflicting Interests

The author(s) declared no potential conflicts of interest with respect to the research, authorship, and/or publication of this article.

### Funding

The author(s) disclosed receipt of the following financial support for the research, authorship, and/or publication of this article: This work was partially supported by the Ministry of Health and IDI-IRCCS, RC to EC.

### Ethical Statement

The study protocol was approved by the Independent Ethical Committee of “Policlinico Tor Vergata” (No. 180/18). All experimental procedures were carried out according to the Code of Ethics of the World Medical Association (Declaration of Helsinki).

## Informed Consent

Informed consent was obtained from all patients prior to surgery. Specimens were handled and carried out in accordance with the approved guidelines. Each patient provided informed written consent for every surgical procedure.

## ORCID iDs

Marco Meloni  <https://orcid.org/0000-0003-3789-9622>

Luigi Uccioli  <https://orcid.org/0000-0001-5087-2091>

## References

- Gherman D, Dumitrescu CI, Ciocan A, Melincovici CS. Histopathological changes in major amputations due to diabetic foot—a review. *Rom J Morphol Embryol*. 2018;59:699-702.
- Brocco E, Ninkovic S, Marin M, et al. Diabetic foot management: multidisciplinary approach for advanced lesion rescue. *J Cardiovasc Surg (Torino)*. 2018;59:670-684.
- Sinwar PD. The diabetic foot management—recent advance. *Int J Surg*. 2015;15:27-30.
- Armstrong DG, Boulton AJM, Bus SA. Diabetic foot ulcers and their recurrence. *N Engl J Med*. 2017;376:2367-2375.
- Wang J, Gao L. New progress in the treatment of chronic wound of diabetic foot [in Chinese]. *Zhongguo Xiu Fu Chong Jian Wai Ke Za Zhi*. 2018;32:832-837.
- Yusof MI, Al-Astani AD, Jaafar H, Rashid FA. Morphometric analysis of skin microvasculature in the diabetic foot. *Singapore Med J*. 2008;49:100-104.
- Vuorisalo S, Venermo M, Lepäntalo M. Treatment of diabetic foot ulcers. *J Cardiovasc Surg (Torino)*. 2009;50:275-291.
- Țânțu MM, Man GM, Rogozea LM, et al. Diabetic foot—epidemiological and histopathological aspects. *Rom J Morphol Embryol*. 2018;59:895-902.
- Driver VR, Lavery LA, Reyzelman AM, et al. A clinical trial of Integra template for diabetic foot ulcer treatment. *Wound Repair Regen*. 2015;23:891-900. doi:10.1111/wrr.12357
- Cazzell S, Vayser D, Pham H, et al. A randomized clinical trial of a human acellular dermal matrix demonstrated superior healing rates for chronic diabetic foot ulcers over conventional care and an active acellular dermal matrix comparator. *Wound Repair Regen*. 2017;25:483-497. doi:10.1111/wrr.12551
- Lucich EA, Rendon JL, Valerio IL. Advances in addressing full-thickness skin defects: a review of dermal and epidermal substitutes. *Regen Med*. 2018;13:443-456.
- Uccioli L, Meloni M, Izzo V, Giurato L. Use of Nevelia dermal-epidermal regenerative template in the management of ischemic diabetic foot postsurgical wounds. *Int J Low Extrem Wounds*. Published online January 29, 2020. doi:10.1177/1534734619896460
- Kallis PJ, Friedman AJ. Collagen powder in wound healing. *J Drugs Dermatol*. 2018;17:403-408.
- Witherell CE, Graney PL, Freytes DO, Weingarten MS, Spiller KL. Response of human macrophages to wound matrices in vitro. *Wound Repair Regen*. 2016;24:514-524.
- Brown BN, Ratner BD, Goodman SB, Amar S, Badylak SF. Macrophage polarization: an opportunity for improved outcomes in biomaterials and regenerative medicine. *Bio-materials*. 2012;33:3792-3802.
- Varela P, Sartori S, Viebahn R, Salber J, Ciardelli G. Macrophage immunomodulation: an indispensable tool to evaluate the performance of wound dressing biomaterials. *J Appl Biomater Funct Mater*. 2019;17:2280800019830355.
- Armstrong DG, Lavery LA, Harkless LB. Validation of a diabetic wound classification system. The contribution of depth, infection, and ischemia to risk of amputation. *Diabetes Care*. 1998;21:855-859.
- Sheehan P, Jones P, Giurini JM, Caselli A, Veves A. Percent change in wound area of diabetic foot ulcers over a 4-week period is a robust predictor of complete healing in a 12-week prospective trial. *Plast Reconstr Surg*. 2006;117(7 suppl):239S-244S.
- International Working Group on the Diabetic Foot. IWGDF guidelines on the prevention and management of the diabetic foot disease. Published 2019. Accessed July 14, 2020. <https://iwgdfguidelines.org/wp-content/uploads/2019/05/IWGDF-Guidelines-2019.pdf>
- Sorg H, Tilkorn DJ, Hager S, Hauser J, Mirastschijski U. Skin wound healing: an update on the current knowledge and concepts. *Eur Surg Res*. 2017;58:81-94.
- Lazarus GS, Cooper DM, Knighton DR, et al. Definitions and guidelines for assessment of wounds and evaluation of healing. *Arch Dermatol*. 1994;130:489-493.
- Hesketh M, Sahin KB, West ZE, Murray RZ. Macrophage phenotypes regulate scar formation and chronic wound healing. *Int J Mol Sci*. 2017;18:1545.
- Koh TJ, DiPietro LA. Inflammation and wound healing: the role of the macrophage. *Expert Rev Mol Med*. 2011;13:e23.
- Krzyszczczyk P, Schloss R, Palmer A, Berthiaume F. The role of macrophages in acute and chronic wound healing and interventions to promote pro-wound healing phenotypes. *Front Physiol*. 2018;9:419.
- Mantovani A, Biswas SK, Galdiero MR, Sica A, Locati M. Macrophage plasticity and polarization in tissue repair and remodeling. *J Pathol*. 2013;229:176-185.
- Chistiakov DA, Killingsworth MC, Myasoedova VA, Orekhov AN, Bobryshev YV. CD68/macrosialin: not just a histochemical marker. *Lab Invest*. 2017;97:4-13.
- Vogel DYS, Glim JE, Stavenuiter AWD, et al. Human macrophage polarization in vitro: maturation and activation methods compared. *Immunobiology*. 2014;219:695-703.
- Larouche J, Sheoran S, Maruyama K, Martino MM. Immune regulation of skin wound healing: mechanisms and novel therapeutic targets. *Adv Wound Care (New Rochelle)*. 2018;7:209-231.
- Boniakowski AE, Kimball AS, Jacobs BN, Kunkel SL, Gallagher KA. Macrophage-mediated inflammation in normal and diabetic wound healing. *J Immunol*. 2017;199:17-24.
- Zomer HD, Jeremias TDS, Ratner B, Trentin AG. Mesenchymal stromal cells from dermal and adipose tissues induce macrophage polarization to a pro-repair phenotype and improve skin wound healing. *Cytotherapy*. 2020;22:247-250. doi:10.1016/j.jcyt.2020.02.003
- De Angelis B, Orlandi F, D'Autilio MFLM, et al. Long-term follow-up comparison of two different bi-layer dermal substitutes in tissue regeneration: clinical outcomes and histological findings. *Int Wound J*. 2018;15:695-706. doi:10.1111/iwj.12912